

THE EFFECT OF PERINDOPRIL ADMINISTRATION ON LEFT VENTRICULAR REMODELING IN PATIENTS WITH ACUTE MYOCARDIAL INFARCTION: A SYSTEMATIC REVIEW

Chabib Fachry Albab¹, Almas Talida Habibah², Faiq Murteza

¹Faculty of Medicine, Airlangga University

²Faculty of Medicine, Sebelas Maret University

³Ibnu Sina Hospital, Bojonegoro, Indonesia

Email: fachryalbab55@gmail.com¹, almastalida56@gmail.com², faiqmurteza0@gmail.com³

ABSTRAK

Infark Miokard Akut (AMI) terjadi akibat penyumbatan arteri koroner, menyebabkan nekrosis sel dan gejala seperti disfungsi peredaran darah. Terapi reperfusi, meskipun bermanfaat, memiliki risiko seperti kerusakan miokard. ACEI, seperti perindopril, menjanjikan dalam remodeling ventrikel pasca AMI, mengurangi hipertensi kronis dan memperbaiki disfungsi diastolik. Proses penyembuhan melibatkan interaksi rumit yang mempengaruhi metabolisme kolagen dan pembesaran kardiomyosit. Namun, penggunaan klinis ACEI bergantung pada kontraindikasi. Tinjauan sistematis ini bertujuan untuk menilai secara komprehensif bukti-bukti yang ada mengenai pemberian Perindopril pada pasien AMI. Pencarian komprehensif dari database PubMed (MEDLINE), ScienceDirect (Embase), dan Cochrane Library menghasilkan 371 laporan, dimana 3 manuskrip dimasukkan dalam tinjauan. Dua penelitian melaporkan bahwa pemberian perindopril mengurangi remodeling ventrikel kiri progresif pada pasien AMI setelah revaskularisasi. Terdapat pengurangan risiko remodeling secara absolut dan hasilnya menunjukkan penurunan parameter remodeling ventrikel kiri meliputi peningkatan LVESD, LVESDD, IVSD, LVPWD, dan LVEF. Sementara itu, sebuah penelitian menunjukkan hasil berbeda. Perindopril merupakan faktor pemicu fibrosis yang kuat, yang mendorong fibrosis miokard melalui beberapa faktor biokimia, termasuk aldosteron, faktor pertumbuhan jaringan ikat, osteopontin. Perindopril dapat menghambat fibrosis miokard dengan menekan ekspresi faktor-faktor ini. Studi ini menyoroti dampak perindopril pada remodeling ventrikel kiri pada pasien infark miokard akut. Mengingat kombinasinya dengan obat lain memerlukan penyelidikan lebih lanjut, karena penelitian terbatas telah dilakukan pada subjek manusia.

Kata Kunci: Perindopril, Remodeling Ventrikel Kiri, Infark Miokard Akut.

ABSTRACT

Acute Myocardial Infarction (AMI) results from coronary artery blockage, causing cell necrosis and symptoms like circulatory dysfunction. Reperfusion therapy, though beneficial, poses risks like myocardial damage. ACEIs, such as perindopril, show promise in post-AMI ventricular remodeling, mitigating chronic hypertension and improving diastolic dysfunction. The healing process involves intricate interactions affecting collagen metabolism and cardiomyocyte enlargement. Clinical use of ACEIs, however, is contingent on contraindications. This systematic review aims to comprehensively assess the existing body of evidence regarding the administration of Perindopril in patients with AMI. A comprehensive search of PubMed (MEDLINE), ScienceDirect (Embase), and Cochrane Library databases yielded 371 reports, of which 3 manuscripts were included in the review. Two studies reported that perindopril administration reduced progressive left ventricular remodeling in patients with AMI after revascularization. There was an absolute risk reduction of remodeling and the results showed a decrease in left ventricular remodeling parameters including LVESD, LVESDD, IVSD, LVPWD, and LVEF improvement. Meanwhile, one study showed different results. Perindopril was potent fibrosis-inducing factors, which promote myocardial fibrosis by way of several biochemical factors, including aldosterone, connective tissue growth factor, osteopontin. Perindopril may inhibit myocardial fibrosis by suppressing the expression of these factors. The study highlighted perindopril's impact on left

ventricular remodeling in acute myocardial infarction patients. Considering its combination with other drugs requires further investigation, as limited research has been conducted on human subjects.

Keywords: *Perindopril, Left Ventricular Remodeling, Acute Myocardial Infarction.*

INTRODUCTION

Acute Myocardial Infarction (AMI) refers to the necrosis of myocardial cells due to the interruption of blood supply to the coronary arteries, leading to ischemia and hypoxia. The clinical manifestations encompass acute circulatory dysfunction, cardiac insufficiency, thoracic discomfort, and irregular heart rhythm (Culic et al., 2003; Van de Werf et al., 2009; Steg et al., 2012). Cardiac dysfunction is a significant complication of AMI that arises due to two primary mechanisms: (i) impaired contractility of cardiomyocytes within the infarcted region; and (ii) Left ventricular (LV) remodeling initiates at the onset of myocardial infarction (MI) and endures thereafter (Cerisano et al, 2007). Despite the potential benefits of reperfusion in salvaging the ischaemic myocardium and reducing left ventricular (LV) remodeling in cases of moderate acute myocardial infarction (AMI), it is important to acknowledge the associated drawbacks. Reperfusion therapy can lead to injury, myocardial damage, microvascular damage, and persistent LV dysfunction. The process of healing following the reperfusion of acute myocardial infarction (AMI) is a multifaceted and ever-changing phenomenon. It involves the presence of excessive free radicals and heightened activity of different cells, cytokines, growth factors, proteins, and molecules. These components play a role in the disruption of collagen metabolism and the enlargement of cardiomyocytes, not only in the area affected by the infarction but also in the surrounding non-infarcted regions (Jugdutt, 1997 and Frangogiannis et al, 2000).

During the recovery period, angiotensin-converting enzyme inhibitors (ACEIs) have shown significant efficacy in enhancing ventricular remodeling among patients with acute myocardial infarction (AMI). According to clinical recommendations, ACEI medications are recommended for patients with AMI after undergoing vascular remodeling. However, this approach may not be suitable for patients who have contraindications (Mathews et al., 2015). Perindopril, an ACEI, has shown promise in cardiovascular protection. The complete clarification of the mechanisms involved has not yet been achieved. It has been reported that chronic hypertension can be mitigated by the use of ACEIs, as they have the ability to reduce myocardial fibrosis and improve diastolic dysfunction. (Diez et al, 2002 and Yoshida et al, 2004) and To ensure the avoidance of detrimental collagen metabolism and left ventricular diastolic dysfunction during the healing process following myocardial infarction in a canine model (Jugdutt, 1997).

This systematic review aims to comprehensively assess the existing body of evidence regarding the administration of Perindopril in patients with AMI. By focusing specifically on its impact on left ventricular remodeling, the review seeks to elucidate the potential benefits or limitations associated with Perindopril therapy in this critical clinical context.

RESEARCH METHODS

Eligibility Criteria

We conducted a comprehensive literature search of English-language clinical studies that reported any effect of perindopril administration on left ventricular remodeling in patients with acute myocardial infarction. No restrictions were made about country, age or gender. Articles that did not contain primary data, such as review articles, were not included in the study. During the full-text screening, only studies that specified the effect of perindopril administration on left ventricular remodeling in patients with acute myocardial infarction were selected.

Search Strategy and Information Sources

A comprehensive search strategy was conducted, incorporating the following search terms: “perindopril” AND “left ventricular remodeling” AND “acute myocardial infarction”, along with their related MeSH terms, synonyms, and elaboration. The literature review was independently conducted by two authors, who reviewed PubMed (MEDLINE), ScienceDirect (Embase), and Cochrane Library databases (access date November 30, 2023, 10:35 a.m.). The search was limited to English-language publications with no limitation on the year of publication. No additional filters were utilized during the search; however, subsequently, the articles were manually selected. Furthermore, apart from conducting electronic searches, we manually examined the reference lists of pertinent articles to uncover supplementary studies.

Data Collection Process

Two authors conducted independent data collection from chosen reports. The selection of articles was based on their title and abstracts to ensure their relevance to the systematic review. No automated tools were utilized during the selection process. The data was extracted into Excel for further analysis. From selected studies, we collected author/year of publication, sample size, mean age, female, comorbidities, study design, drug administration and dose, interval between AMI and start of treatment, follow-up duration, and outcomes. Continuous variables were represented as mean \pm standard deviation or range of outcomes. Categorical variables were represented as percentages.

Risk of Bias

Risk of bias assessment was conducted by two authors working independently. Disagreements were resolved by discussion with a senior author. The tool used for assessment was the RoB2 critical appraisal checklist for randomized control trials and the Newcastle Ottawa Scale (NOS) for observational studies.

Data Analysis

Analysis was carried out on the presence or absence of left ventricular remodeling by comparing the results before and after administration of perindopril. The parameters used are left ventricular end systolic volume index, left ventricular end diastolic volume index, left ventricular end systolic volume, left ventricular end systolic diameter, left ventricular end diastolic diameter, and posterior wall diameter. We also analyzed other factors that could influence the results such as age, patient comorbidities, drug dose, and perindopril administration interval with the occurrence of AMI.

RESULTS AND DISCUSSION

Results

Selection of Studies

The process of selecting studies encompassed a grand total of 371 publications that were initially identified. Following the elimination of duplicates (n=13) and the exclusion of papers that were deemed irrelevant to the topic or did not meet the predetermined inclusion criteria (n=351). Initially, two reviewers conducted a thorough examination of the titles and abstracts of the collected studies in order to identify suitable publications. Subsequently, the researchers independently scrutinized the full-text records of the remaining seven studies that successfully passed this initial screening phase to determine their eligibility. It is important to note that no automated tools were employed throughout this meticulous process. During the full-text evaluation stage, the two reviewers, who had previously conducted the screening process,

thoroughly examined the complete texts of the research. Through discussion and collaboration, the reviewers were able to resolve any discrepancies in their assessments of both the title/abstract and the entire text. As a result, a total of 3 manuscripts were deemed suitable for inclusion in the systematic review (Figure 1).

Quality of Studies

The risk of bias in each included study was assessed and is presented in Figure 2 and Table 3 (Supplementary file). One study was assessed with RoB-2 tools and two studies were assessed with NOS. The summarized critical appraisal checklist shows that the risks are generally low risk of bias for each domain: randomization process, deviations from intended interventions, missing outcome data, measurement of outcome, and selection of the reported result. All the studies that were included in the analysis demonstrated a reliable selection process, as the study populations adequately represented the effect of perindopril administration on left ventricular remodeling in patients with acute myocardial infarction. In addition, good comparative and exposure aspects were observed. The final evaluation of the studies revealed that they had a mean NOS score above 7, signifying that the follow-up duration was satisfactory and the dropout rates were reasonably low. No detection bias, or problems with the measurement or classification of outcomes, were found in any of the studies. The statistical analysis provided in each study was deemed to have high methodological quality.

Study Description

Two of the three studies were prospective cohort studies. One study was a randomized control trial. A total of 1,514 samples were involved in the entire study with an average age ranging from 57.5-72 years. The comorbidities in the 3 studies were almost the same, with smoking, DM, HT, and hyperlipidemia having the highest percentage.

The studies by Ferrari et al and Lin et al focused only on the effect of perindopril administration on left ventricular remodeling. Meanwhile, the study by Li et al also analyzed the effect of administering perindopril combined with losartan on left ventricular remodeling. Based on two studies, administration of perindopril can reduce left ventricular remodeling. In the study by Ferrari et al, before therapy was given, the LVEDV value was 81 ± 23 mL, LVESV 34 ± 14 mL, and LVEF $59 \pm 8\%$. After being given perindopril therapy at a dose of 8 mg/d for 12 months, the results showed that there was an absolute risk reduction of remodeling $\geq 8\%$: 23 (17 to 30), $p < .001$. In Lin et al's study, the patient's baseline characteristics showed LVESD 37.8 ± 3.5 mm, LVESDD 51.3 ± 4.3 mm, IVSD 11.7 ± 2.3 mm, LVPWD 14.8 ± 2.6 mm, and LVEF $43.5 \pm 7.6\%$. After being given perindopril therapy with an initial dose of 2 mg/d, then increased by 2 mg/qd every 1–2 weeks, the results showed a decrease in left ventricular remodeling parameters including LVESD 30.4 ± 4.4 mm, LVESDD 44.2 ± 4.6 mm, IVSD 11.3 ± 2.5 mm, LVPWD 10.3 ± 1.9 mm, and LVEF improvement $57.3 \pm 5.0\%$. This study was conducted for 6 months. Meanwhile, Li et al's study showed different results. In samples that were only given perindopril, it did not reduce left ventricular remodeling parameters but was able to improve the patient's LVEF. For patients with acute MI, combination treatment with perindopril and losartan significantly inhibited LV remodeling and improved LV function.

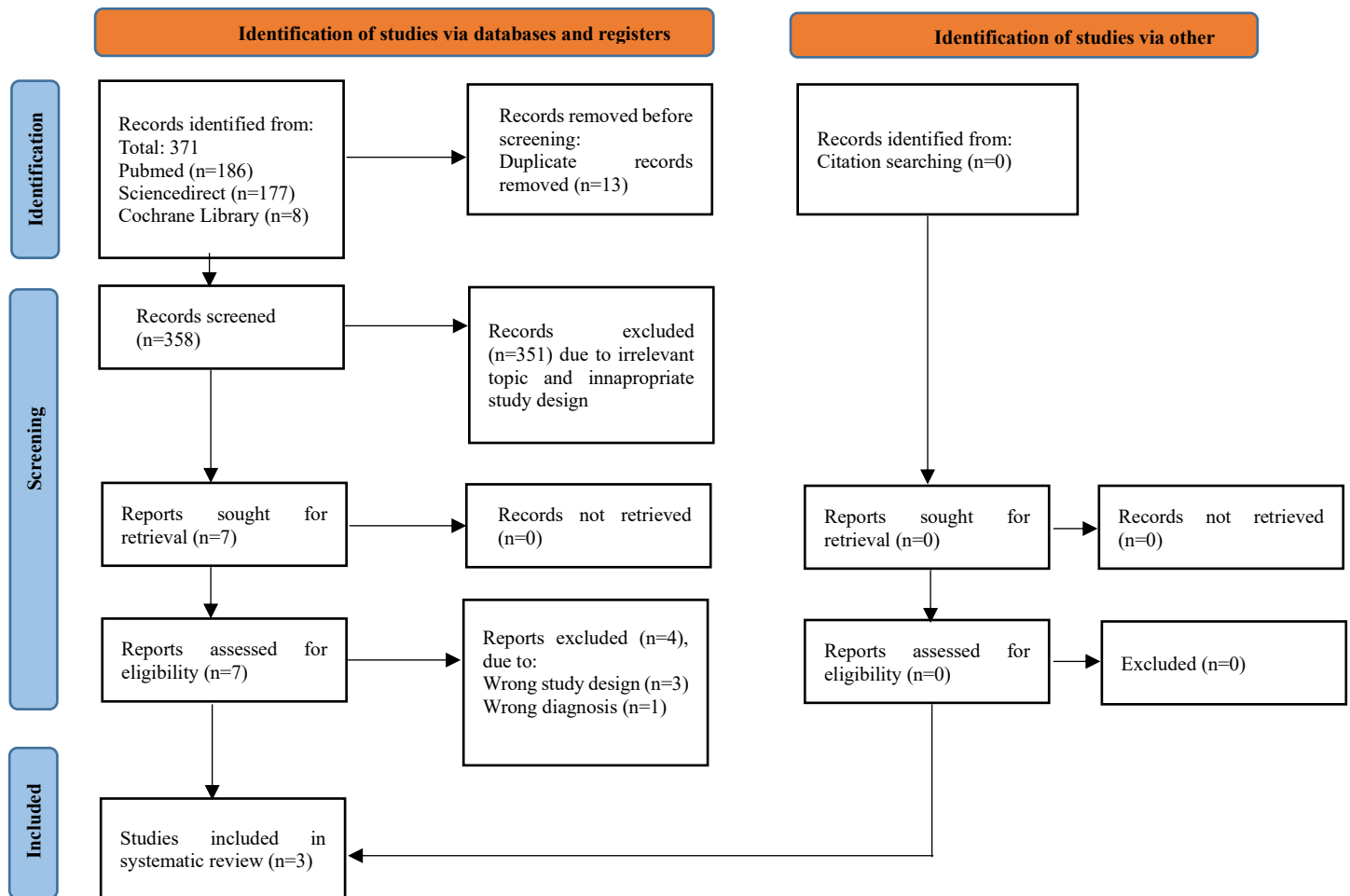


Figure 1. PRISMA Flowchart

Table 1. Characteristics of the investigated studies

Author/Year of Publication	Sample Size (n)	Female (n)	Mean Age (mean \pm SD)	Comorbidities	Study Design
Ferrari et al, 2006	1252	436	72 \pm 6	Stroke/TIA, HF, PVD, HT, DM, hyperlipidemia, smoking	RCT
Li et al, 2009	37	10	64.4 \pm 6.4	Smoking, HT, hyperlipidemia, DM	Cohort prospective
Lin et al, 2019	225	102	57.5 \pm 7.9	Smoking, alcohol	Cohort prospective

Table 2. Studies results

Author/Year of Publication	Drug Administration and Dose	Interval Between AMI and	Outcome		Follow Up Duration
			PreTreatment	Post Treatment	

		Start of Treatment			
Ferrari et al, 2006	Perindopril 8mg/d	11 ± 4 days	LVEDV 81 ± 23 mL LVESV 34 ± 14 mL LVEF 59 ± 8%	NA (Absolute risk reduction of remodeling ≥8%: 23 (17 to 30), p<.001)	12 months
Li et al, 2009	Perindopril 2-4mg/d	1 day	LVEDVI 58.54 ± 9.81 mL/m ² LVESVI 35.76 ± 5.89 mL/m ² LVEDd 51.95 ± 3.49 mm PWt 10.21 ± 0.80 mm LVEF 37.49 ± 5.25%	LVEDVI 78.73 ± 9.7 mL/m ² LVESVI 39.57 ± 5.20 mL/m ² LVEDd 57.14 ± 5.56 mm PWt 11.61 ± 1.21 mm LVEF 45.73 ± 5.60%	3 months
Lin et al, 2019	Perindopril, initial dose 2mg/d, s increased by 2 mg/qd every 1–2 weeks	NA	LVESD 37.8 ± 3.5 mm LVESDD 51.3 ± 4.3 mm IVSD 11.7 ± 2.3 mm LVPWD 14.8 ± 2.6 mm LVEF 43.5 ± 7.6%	LVESD 30.4 ± 4.4 mm LVESDD 44.2 ± 4.6 mm IVSD 11.3 ± 2.5 mm LVPWD 10.3 ± 1.9 mm LVEF 57.3 ± 5.0%	6 months

Discussion

Our systematic review contains three studies that report the effect of perindopril administration on left ventricular remodeling. The findings of the presented studies confirm the existence of a relationship between perindopril administration and left ventricular remodeling. Two studies (Ferrari et al and Lin et al) reported that perindopril administration reduced progressive left ventricular remodeling in patients with AMI after revascularization. This is supported by in vivo research by Murakami et al in 2000. This study investigated the effect of the angiotensin-converting enzyme (ACE) inhibitor perindopril on left ventricular (LV) remodeling and cardiac function in rats with aortic regurgitation (AR). Perindopril effectively suppressed left ventricular remodeling caused by excessive volume and maintained left ventricular function in rats with aortic regurgitation (Murakami et al, 2000). Another study in heart failure patients also showed similar results. The administration of perindopril resulted in a notable reduction in both the frequency and geometric mean titre among patients who tested positive for anti-AT1-AR. This reduction was so significant that it led to complete elimination. Interestingly, these patients experienced a more pronounced improvement in left ventricular remodeling and heart function compared to those who tested negative for anti-AT1-AR after one year of perindopril treatment in conjunction with standard therapy. However, there were no significant differences in endpoint events observed over the subsequent 5-year period. The presence of anti-AT1-AR may serve as a valuable biomarker for identifying the over-activation of the renin-angiotensin-aldosterone system in clinical medication. (Du et al, 2013).

Angiotensin II is the primary hormone generated by the renin-angiotensin system, exerts significant influence over the control of blood pressure (BP) as well as cardiac remodeling. Perindopril erbumine is an ACE inhibitor with extended duration of action, is a prodrug that is metabolized through hydrolysis to produce its active metabolite, perindoprilat (Todd and Fitton, 1991). Perindopril demonstrates notable beneficial impacts on both vascular and myocardial

alterations. The administration of ACE inhibitors effectively counteracts the development of left ventricular hypertrophy (McVeigh, 2001).

The precise mechanisms underlying the advantageous impacts of perindopril on left ventricular remodeling remain to be elucidated. Potential benefits of certain interventions may encompass the mitigation of ventricular wall stress, suppression of detrimental neurohormonal activation, and prevention of myocardial ischemia. Surprisingly, the PERTINENT trial, which is a substudy of the EUROPA trial, conducted in 2003, revealed that perindopril effectively decreases the occurrence of endothelial apoptosis. Apoptosis of myocytes has emerged as a significant biological factor in the process of remodeling, especially among the elderly population (Nian et al., 2004 and Baines and Molkentin, 2005). Despite the widespread utilization of beta blockers (71% at randomization), perindopril's impact on remodeling remained evident. Furthermore, there was no interaction observed between the treatments, indicating that the underlying mechanisms of action for beta blockers and ACE inhibitors are complementary rather than mutually exclusive. In trials conducted on patients with heart failure (HF), the impact of beta blockers on left ventricular (LV) enlargement has consistently shown significant results. These findings indicate a stronger reduction in LV enlargement compared to randomized studies involving ACE inhibitors (Khattar, 2003).

Li et al. conducted a research study that yielded varying outcomes. The study aimed to assess left ventricular remodelling using ultrasonography to measure several parameters, including LV end-diastolic volume index (LVEDVI), LV end-systolic volume index (LVESVI), LVEDd, and PWt. Furthermore, the assessment of cardiac performance was conducted through the measurement of left ventricular ejection fraction (LVEF). Following three months after the acute myocardial infarction (AMI), individuals belonging to the MI + perindopril and MI + losartan groups displayed an expansion of the left ventricle (LV), as evidenced by significant elevations in left ventricular end-diastolic volume index (LVEDVI), left ventricular end-systolic volume index (LVESVI), and left ventricular end-diastolic diameter (LVEDd). Additionally, there was an observed increase in the thickness of the non-infarcted region, denoted by an elevation in posterior wall thickness (PWt) (all $P < 0.05$ compared to the initial measurements within the same group). Nevertheless, the group receiving combination therapy exhibited distinct alterations in these echocardiographic parameters. Specifically, there was an increase in both left ventricular end-diastolic volume index (LVEDVI) and left ventricular end-diastolic diameter (LVEDd), indicating left ventricular dilation. Conversely, left ventricular end-systolic volume index (LVESVI) and posterior wall thickness (PWt) did not exhibit significant changes. These findings suggest that combination therapy not only enhanced left ventricular systolic function but also inhibited hypertrophy in the non-infarcted region. Moreover, the administration of a combination therapy exhibited more pronounced enhancements in left ventricular (LV) function compared to the use of a single drug in isolation.

Numerous research teams have conducted investigations on the impact of ACEIs, ARBs, and their combination on left ventricular (LV) remodeling and function following acute myocardial infarction (AMI). However, the findings from these studies have yielded inconsistent results. Furthermore, it is worth noting that the existing studies encompass both in vitro and in vivo experiments. In their study, Kusuyama et al. (2005) observed that both an ACEI and an ARB exhibited comparable efficacy in preventing left ventricular (LV) remodeling and reducing LV ejection fraction (LVEF) in rats with myocardial infarction (MI). However, contrasting findings have been reported by Tao et al. (2005), who found that ARBs had more pronounced effects than ACEIs, and that combination therapy yielded superior outcomes compared to monotherapy with either drug alone. In vitro and in vivo investigations have substantiated that angiotensin II and aldosterone possess significant fibrosis-inducing properties, thereby promoting myocardial fibrosis through various biochemical factors, including aldosterone, connective tissue growth factor, and osteopontin. The utilization of

angiotensin-converting enzyme inhibitors has been shown to impede myocardial fibrosis by suppressing the expression of these factors. Furthermore, the addition of an angiotensin receptor blocker may yield greater benefits by further suppressing aldosterone expression. However, it is important to note that there has been only one human study conducted thus far, which examined the combination of perindopril and losartan. Consequently, further research is required to validate the existing findings (Li et al., 2009).

This study has weaknesses, including the use of various doses of perindopril and different duration of administration. However, due to limited studies discussing the effect of perindopril on LV remodeling, this can still be accepted. However, an update of the study is needed if more research on perindopril and LV remodeling is performed.

CONCLUSION

For the first time, this study demonstrated the effect of perindopril administration on left ventricular remodeling in patients with acute myocardial infarction. The combination of perindopril with other drugs still needed to be considered because little research had been carried out on human subjects.

DAFTAR PUSTAKA

- Culic V, Miric D, Jukic I (2003) Acute myocardial infarction: differing preinfarction and clinical features according to in farct site and gender. *Int J Cardiol* 90:189–196.
- Van de Werf F, Bax J, Betriu A, et al. (2009) ESC guidelines on management of acute myocardial infarction in patients pre senting with persistent ST-segment elevation. *Rev Esp Car diol* 62:293, e291–247.
- Steg PG, James SK, Atar D, et al. (2012) ESC Guidelines for the management of acute myocardial infarction in patients presenting with ST-segment elevation. *Eur Heart J* 33:2569 2619.
- Cerisano G, Pucci PD, Sulla A et al. Relation between plasma brain natriuretic peptide, serum indexes of collagen type I turnover, and left ventricular remodeling after reperfused acute myocardial infarction. *Am. J. Cardiol.* 2007; 99: 651–6.
- Jugdutt BI. Effect of reperfusion on ventricular mass, topography and function during healing of anterior infarction. *Am. J. Physiol.* 1997; 272: H1205–11.
- Frangogiannis NG, Mendoza LH, Lindsey ML et al. IL-10 is induced in the reperfused myocardium and may modulate the reaction to injury. *J. Immunol.* 2000; 165: 2798–808.
- Diez J, Querejeta R, Lopez B et al. Losartan-dependent regression of myocardial fibrosis is associated with reduction of left ventricular chamber stiffness in hypertensive patients. *Circulation* 2002; 105: 2512–17.
- Yoshida J, Yamamoto K, Mano T et al. AT1 receptor blocker added to ACE inhibitor provides benefits at advanced stage of hypertensive diastolic heart failure. *Hypertension* 2004; 43: 686–91.
- Mathews R, Wang TY, Honeycutt E, et al. (2015) Persistence with secondary prevention medications after acute myocar dial infarction: insights from the TRANSLATE-ACS study. *Am Heart J* 170:62–69.
- Murakami K, Mizushige K, Noma T, Kimura S, Abe Y, Matsuo H. Effects of perindopril on left ventricular remodeling and aortic regurgitation in rats assessed by echocardiography. *Angiology.* 2000 Nov;51(11):943-52. doi: 10.1177/000331970005101107. PMID: 11103863.
- Du Q, Wu J, Wang H, Wang X, Xu L, Zhang Z, Liu J, Zhang J, Chen J, Hakonarson H, Hu A, Zhang L. Perindopril treatment promote left ventricle remodeling in patients with heart failure screened positive for autoantibodies against angiotensin II type 1 receptor. *BMC*

- Cardiovasc Disord. 2013 Oct 31;13:94. doi: 10.1186/1471-2261-13-94. PMID: 24175973; PMCID: PMC3816204.
- Todd PA, Fitton A. Perindopril: a review of its pharmacological properties and therapeutic use in cardiovascular disorders. *Drugs* 1991;42:90–114.
- McVeigh GE. Effects of perindopril on cardiovascular remodeling. *Am J Cardiol.* 2001 Oct 4;88(7A):28i-35i. doi: 10.1016/s0002-9149(01)01919-1. PMID: 11591358.
- Nian M, Lee P, Khaper N, Liu P. Inflammatory cytokines and postmyocardial infarction remodeling. *Circ Res.* 2004;94:1543-1553.
- Baines CP, Molkentin JD. Stress signaling pathways that modulate cardiac myocyte apoptosis. *J Mol Cell Cardiol.* 2005;38:47-62.
- Khattar RS. Effects of ACE-inhibitors and beta-blockers on left ventricular remodeling in chronic heart failure. *Minerva Cardioangiol.* 2003;51:143-154.
- Li L, Liu RY, Zhao XY, Zhang JY, Jia M, Lu PQ. Effects of combination therapy with perindopril and losartan on left ventricular remodeling in patients with myocardial infarction. *Clin Exp Pharmacol Physiol.* 2009 Jul;36(7):704-10. doi: 10.1111/j.1440-1681.2009.05143.x. Epub 2009 Jan 18. PMID: 19207720.
- Kusuyama T, Yoshiyama M, Omura T et al. Angiotensin blockade inhibits osteopontin expression in non-infarcted myocardium after myocardial infarction. *J. Pharmacol. Sci.* 2005; 98: 283–9.
- Tao ZW, Huang YW, Xia Q, Xu QW. Combined effects of ramipril and angiotensin II receptor blocker TCV116 on rat congestive heart failure after myocardial infarction. *Chin. Med. J.* 2005; 118: 146–54.
- Lin P, Li H, Yu T, Liu Y. The Effect of Angiotensin-Converting Enzyme Gene Polymorphisms on the Clinical Efficacy of Perindopril Prescribed for Acute Myocardial Infarction in Chinese Han Patients. *Genet Test Mol Biomarkers.* 2019 May;23(5):316-324. doi: 10.1089/gtmb.2018.0232. Epub 2019 Apr 3. PMID: 30942616.
- Ferrari R; Perindopril and Remodeling in Elderly with Acute Myocardial Infarction Investigators. Effects of angiotensin-converting enzyme inhibition with perindopril on left ventricular remodeling and clinical outcome: results of the randomized Perindopril and Remodeling in Elderly with Acute Myocardial Infarction (PREAMI) Study. *Arch Intern Med.* 2006 Mar 27;166(6):659-66. doi: 10.1001/archinte.166.6.659. PMID: 16567606.